Restaurer la fonction: Alignement cinématique ou alignement mécanique?

A.Deltour MD

Hôpital Delta CHIREC

Bruxelles

Smith+Nephew meeting 30/10/2019 Watford

BKC BRUSSELS KNEE CENTER

Conflit d’intérêt

- Consultance: Smith+Nephew
  Arthrex

BKC
BRUSSELS KNEE CENTER

Définitions

BKC
BRUSSELS KNEE CENTER

Alignement anatomique

- Axe Fémur- Axe Tibia = **6° de VL** par rapport à la verticale

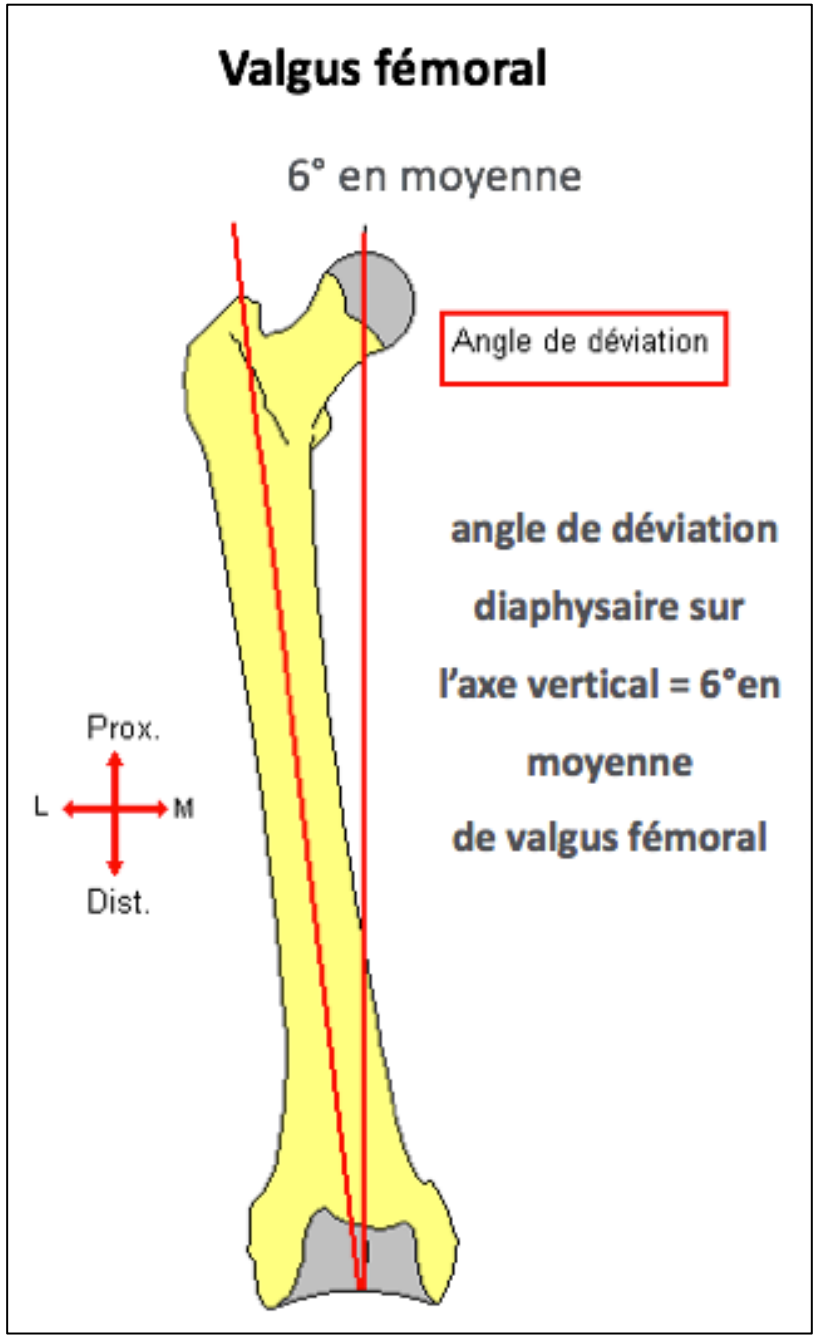

BKC
BRUSSELS KNEE CENTER

Alignement mécanique

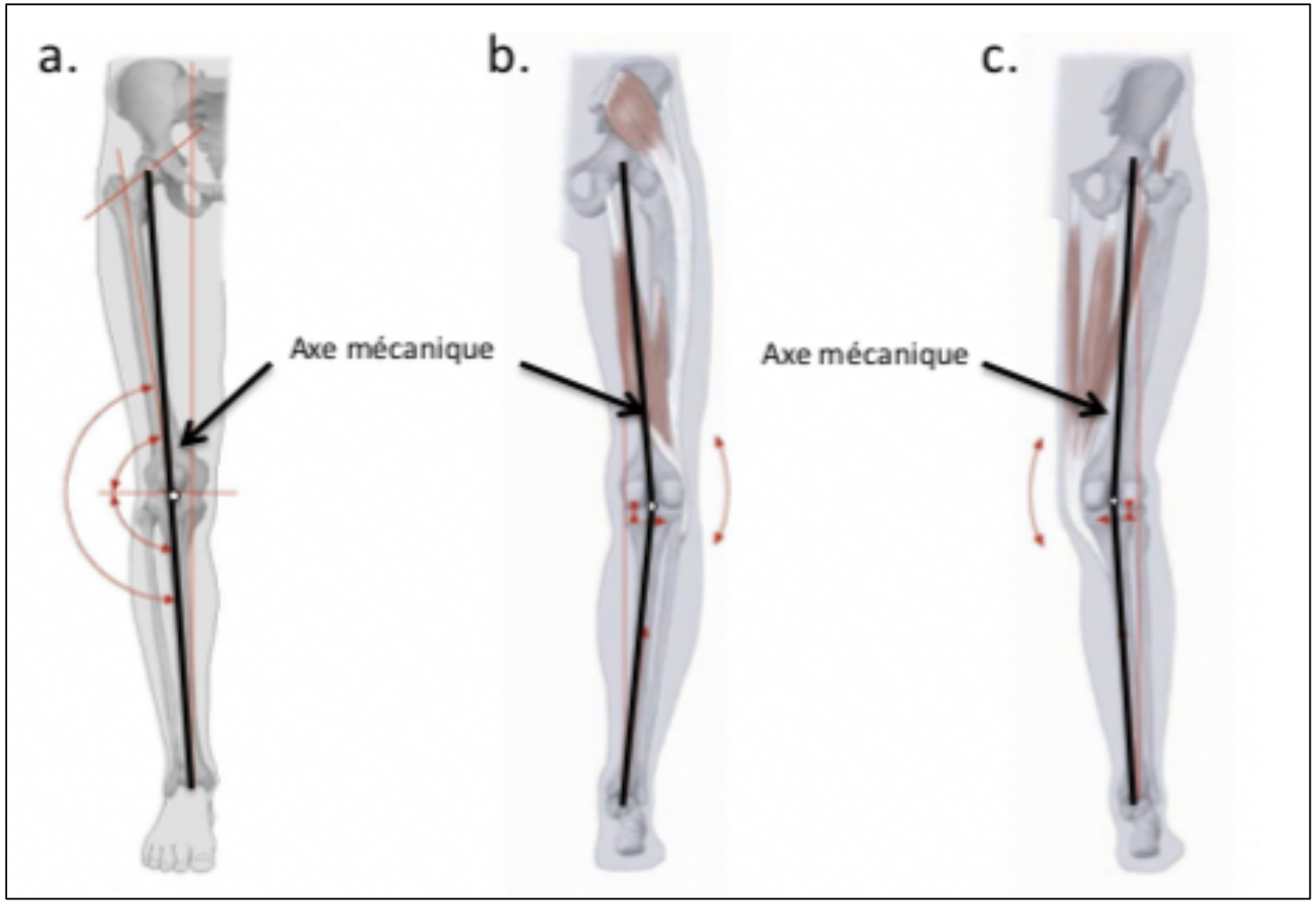

varus valgus

- Centre Tête fémur- centre genou- centre cheville = angle (HKA)
- VARUS : < 180°
- VALGUS: >180°

BKC
BRUSSELS KNEE CENTER

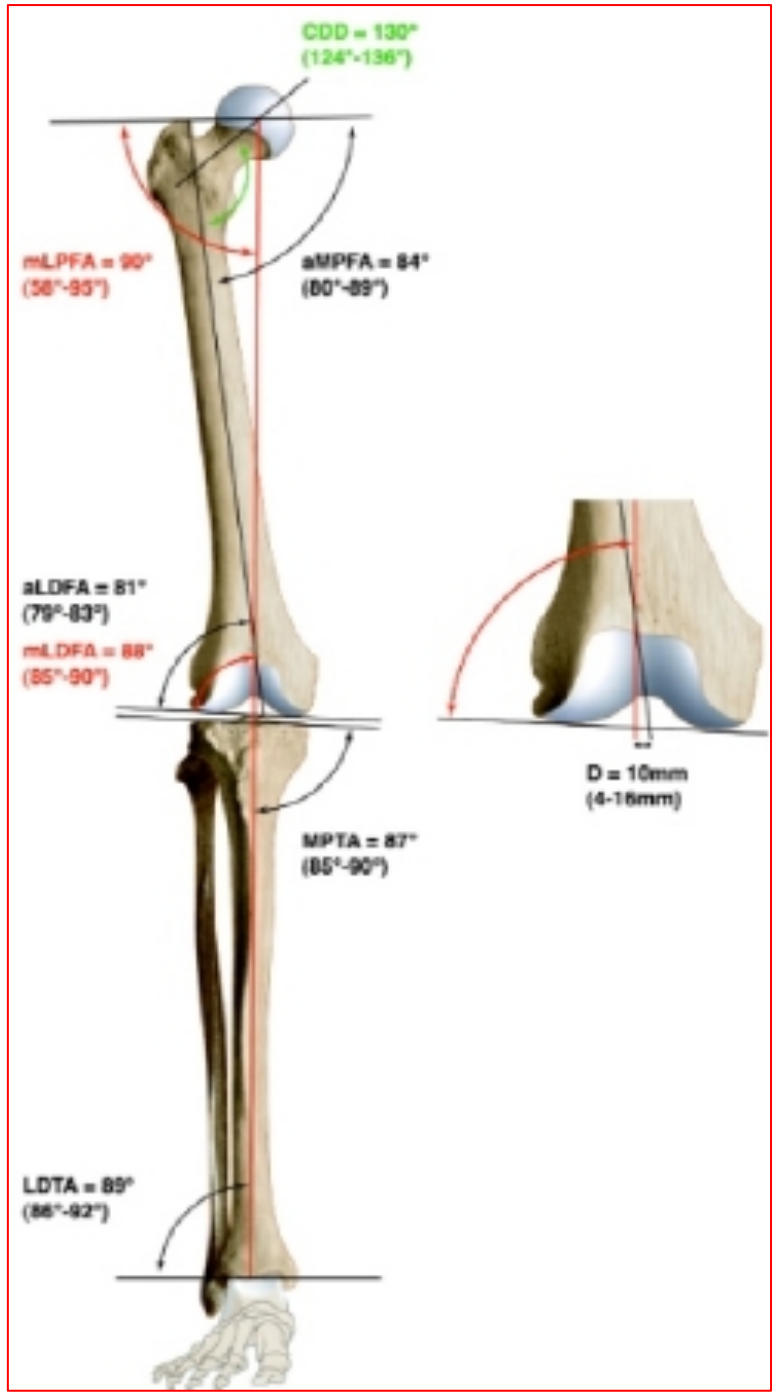

- HKA= mLDFA +MPTA +JLCA

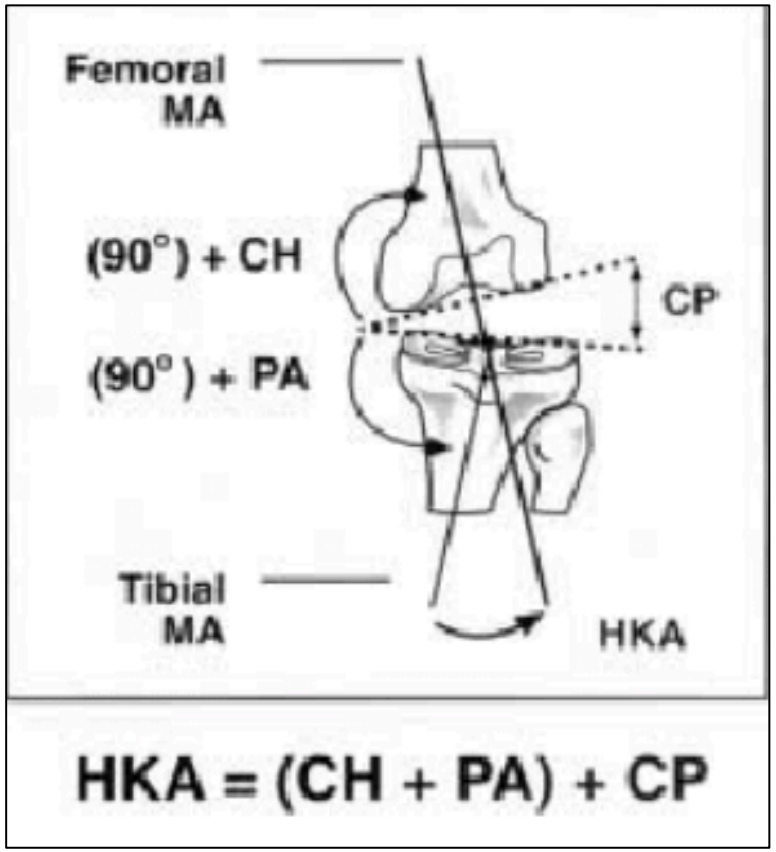

BKC
BRUSSELS KNEE CENTER

Alignement vs Mauvais Alignement

- Idéal= 180° et 6° de VL pour l'alignement anatomique
- Normal= 178°-182°

Mesure sur Goniométrie en charge

BKC
BRUSSELS KNEE CENTER

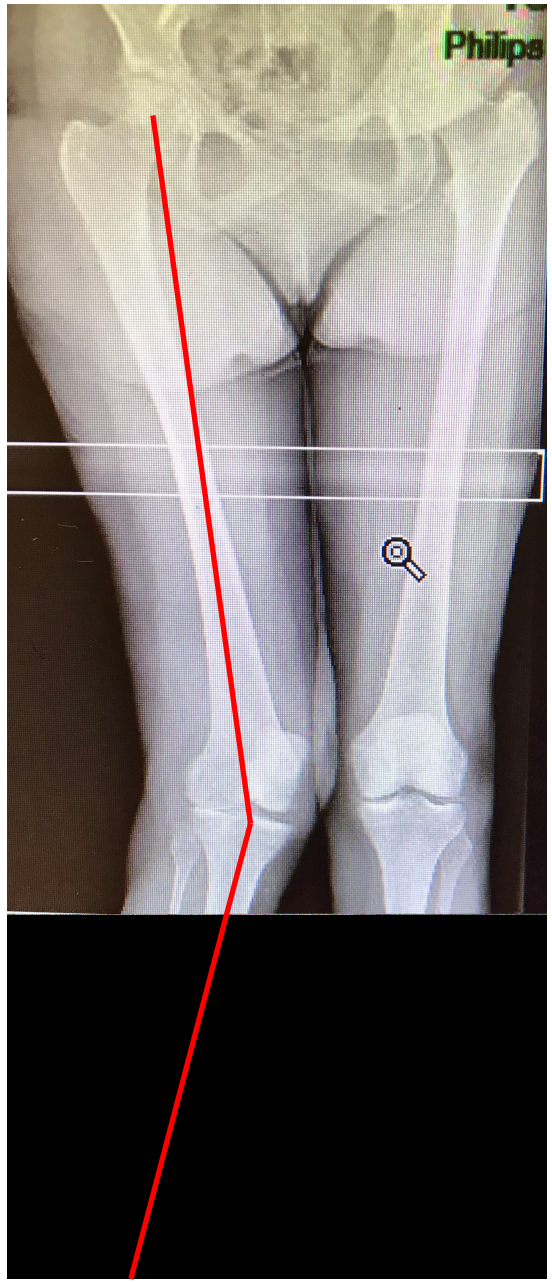

Déformation en Valgus

BKC
BRUSSELS KNEE CENTER

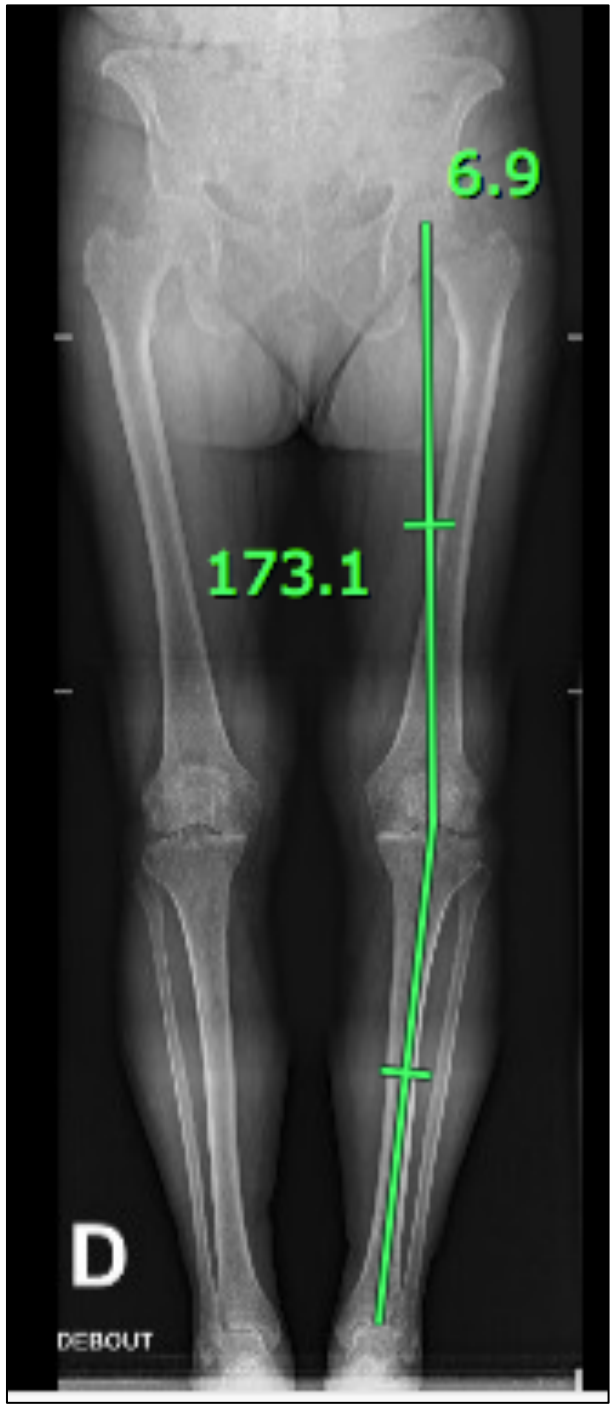

Déformation en varus

BKC
BRUSSELS KNEE CENTER

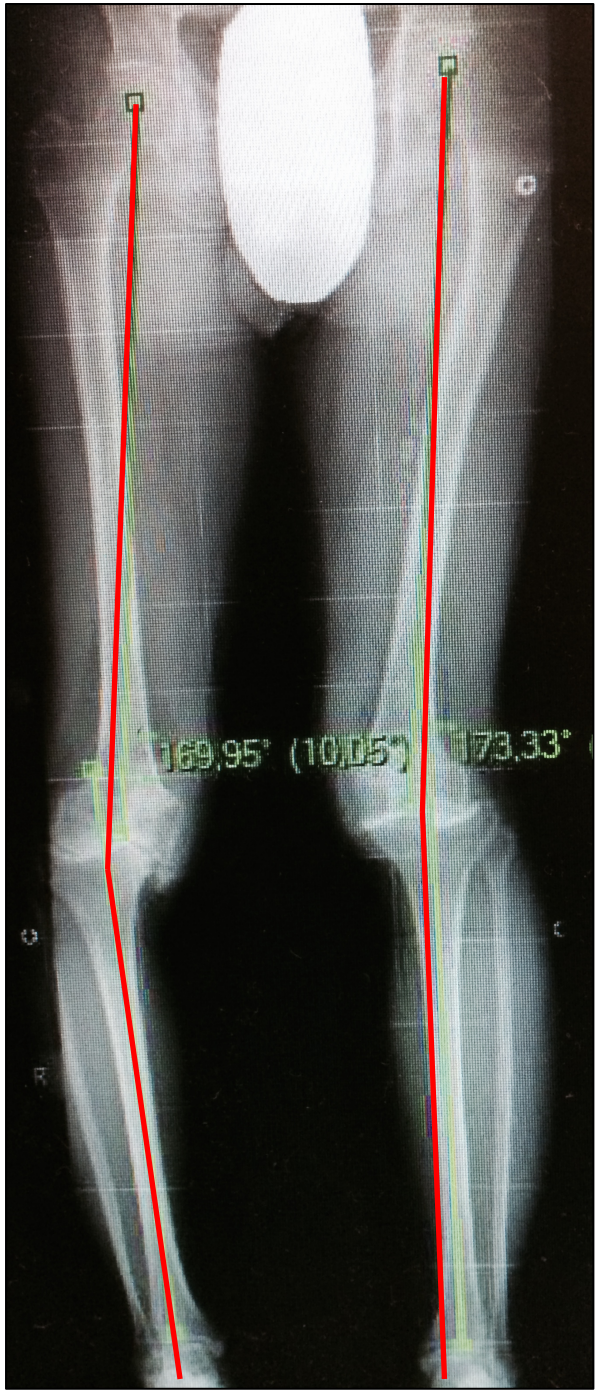

Déformation Intra-articulaire et son impact sur l'alignement

BKC
BRUSSELS KNEE CENTER

Déformation extra articulaire

- Impact en **fonction de la distance** entre l'apex de la déformation et l'articulation.
- Au + la distance est importante au moins sera l'influence sur l'articulation.

BKC
BRUSSELS KNEE CENTER

L'axe d'appui ou ligne de Maquet

- Ligne entre centre tête fémur et centre cheville

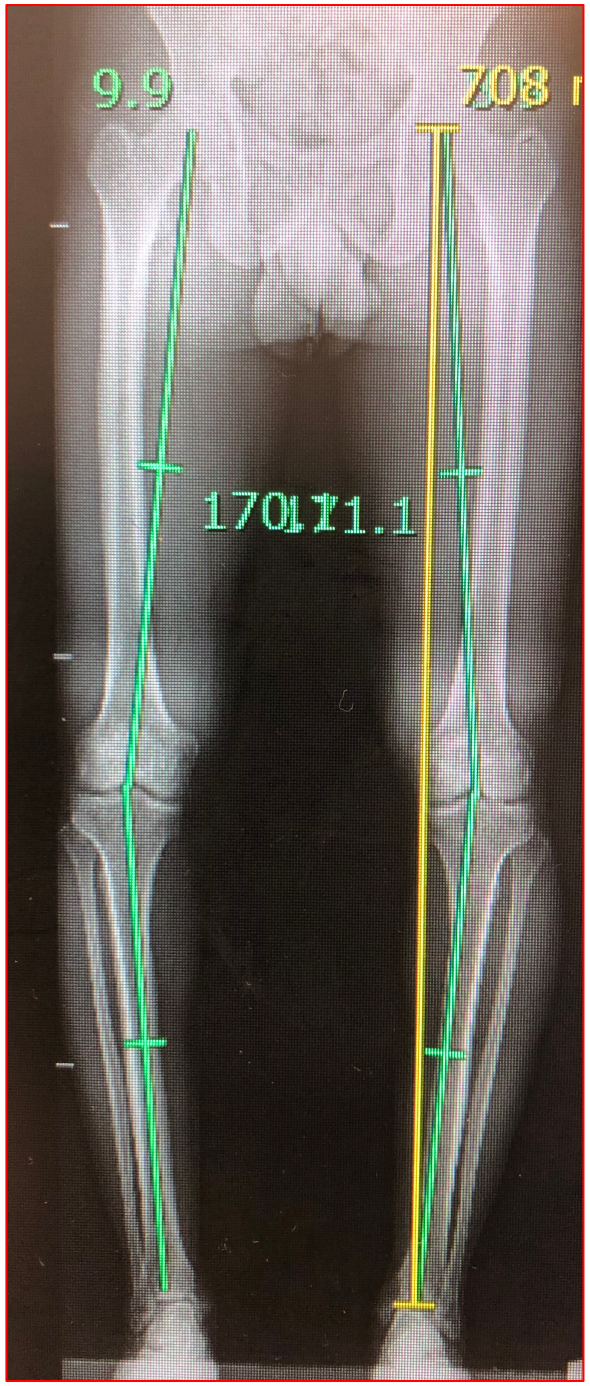

BKC
BRUSSELS KNEE CENTER

Les Théories d'Alignement avec une PTG

- Approches systématiques:

1. Théorie de l'Alignement Mécanique
2. Théorie de l'Alignement Anatomique

- Approche Spécifique: Théorie de l'Alignement Cinématique

- Approches Hybrides:

1. Théorie de l'alignement mécanique ajusté
2. Théorie de l'alignement cinématique restreinte

Théorie de l'Alignement Mécanique neutre Approche systématique

Clin Orthop Relat Res. 1985 Jan-Feb;(192):13-22.

Total knee arthroplasty.

Insall JN, Binazzi R, Soudry M, Mestriner LA.

- HKA=180°
- JLCA= Obliquité = 0°
- LDFA passant de 9°à 6°
- MPTA passant de 3° à 0° de VR
- Ligne de Maquet passant par le centre du genou

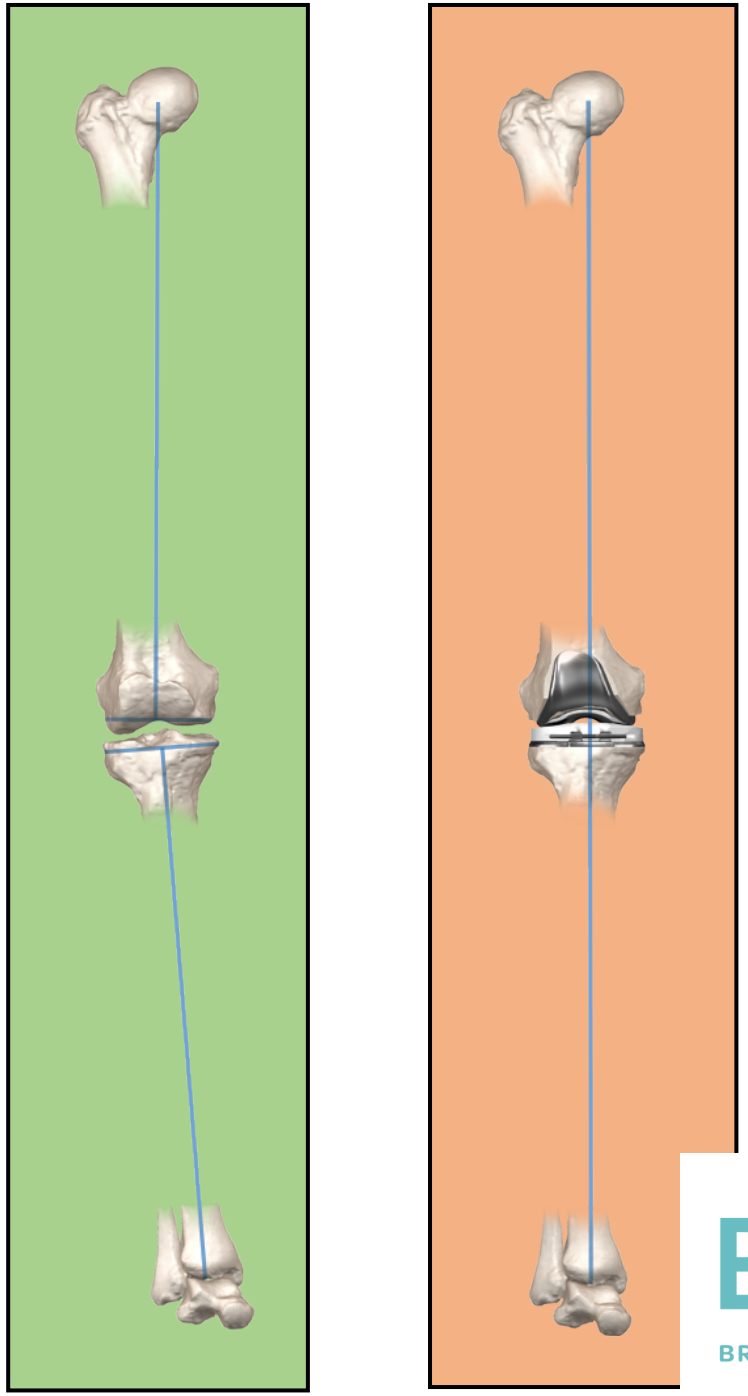

BKC
BRUSSELS KNEE CENTER

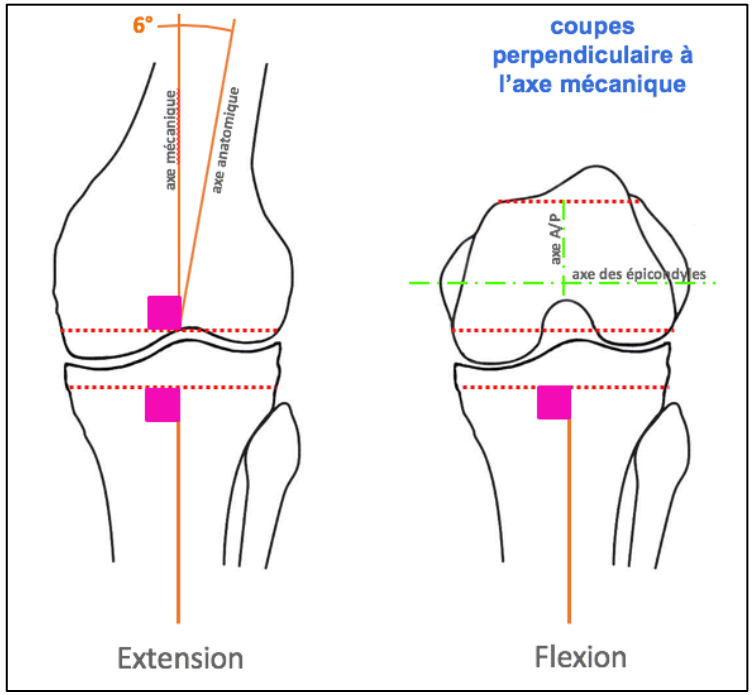
6°
axe mécanique
axe anatomique
coupes
perpendiculaire à
l'axe mécanique
axe A/P
axe des épicondyles
Extension
Flexion

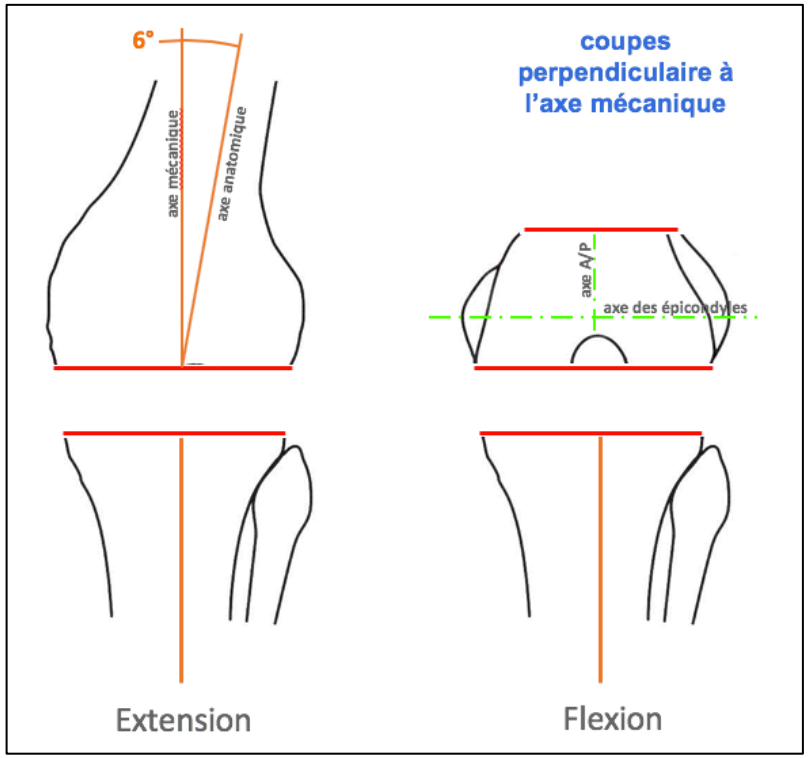
6°
axe mécanique
axe anatomique
coupes
perpendiculaire à
l'axe mécanique
axe A/P
axe des épicondyles
Extension
Flexion

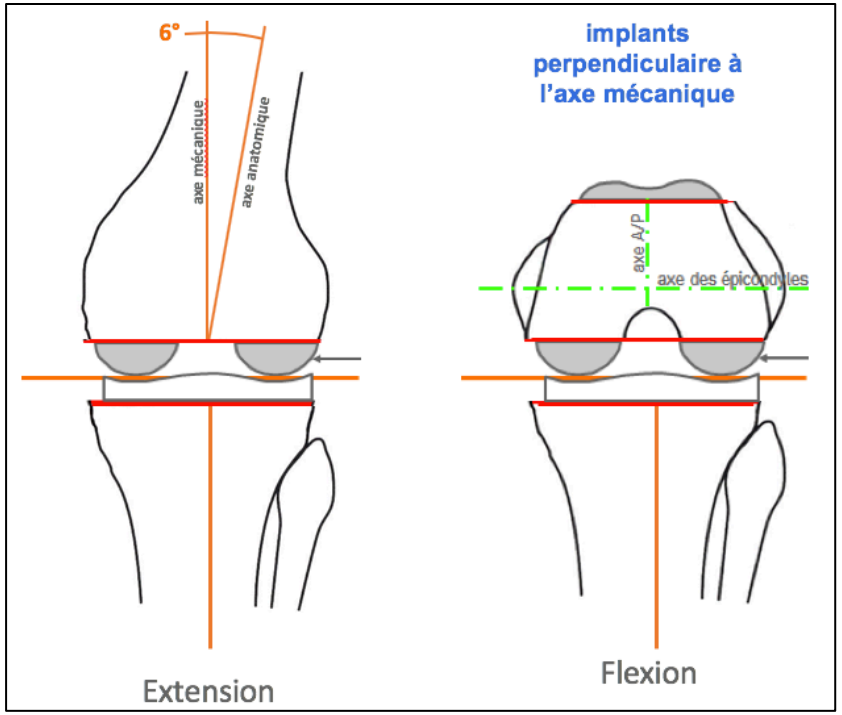
6°
axe mécanique
axe anatomique
implants
perpendiculaire à
l'axe mécanique
axe A/P
axe des épicondyles
Extension
Flexion

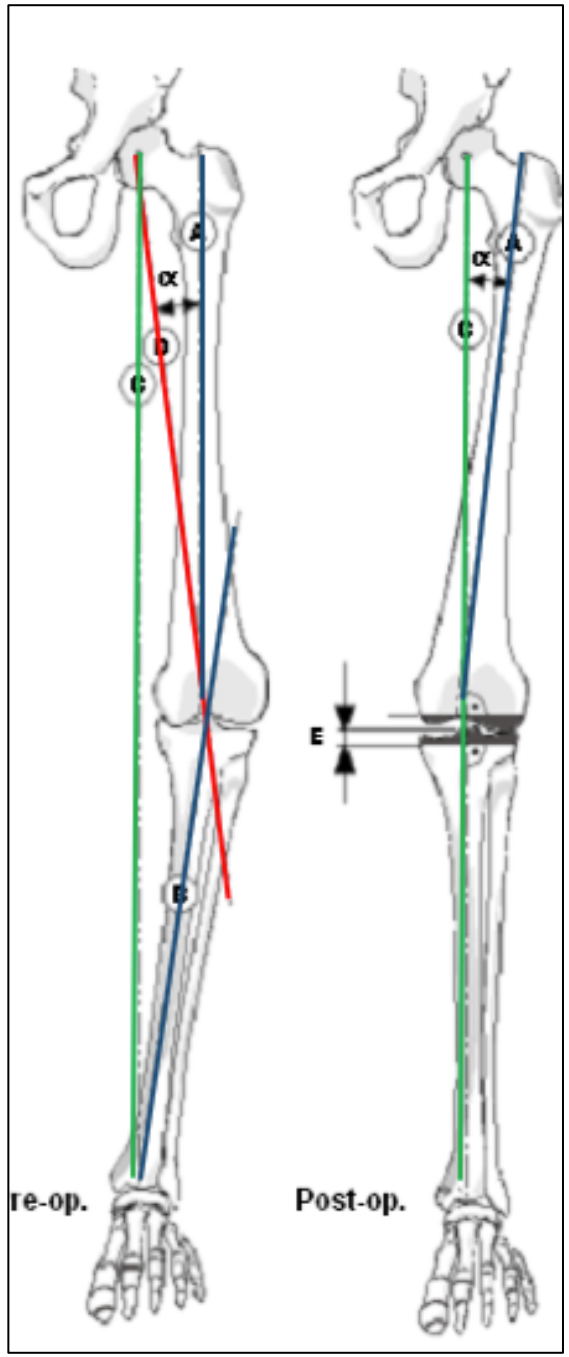
A
α
D
C
B
E
re-op.
Post-op.

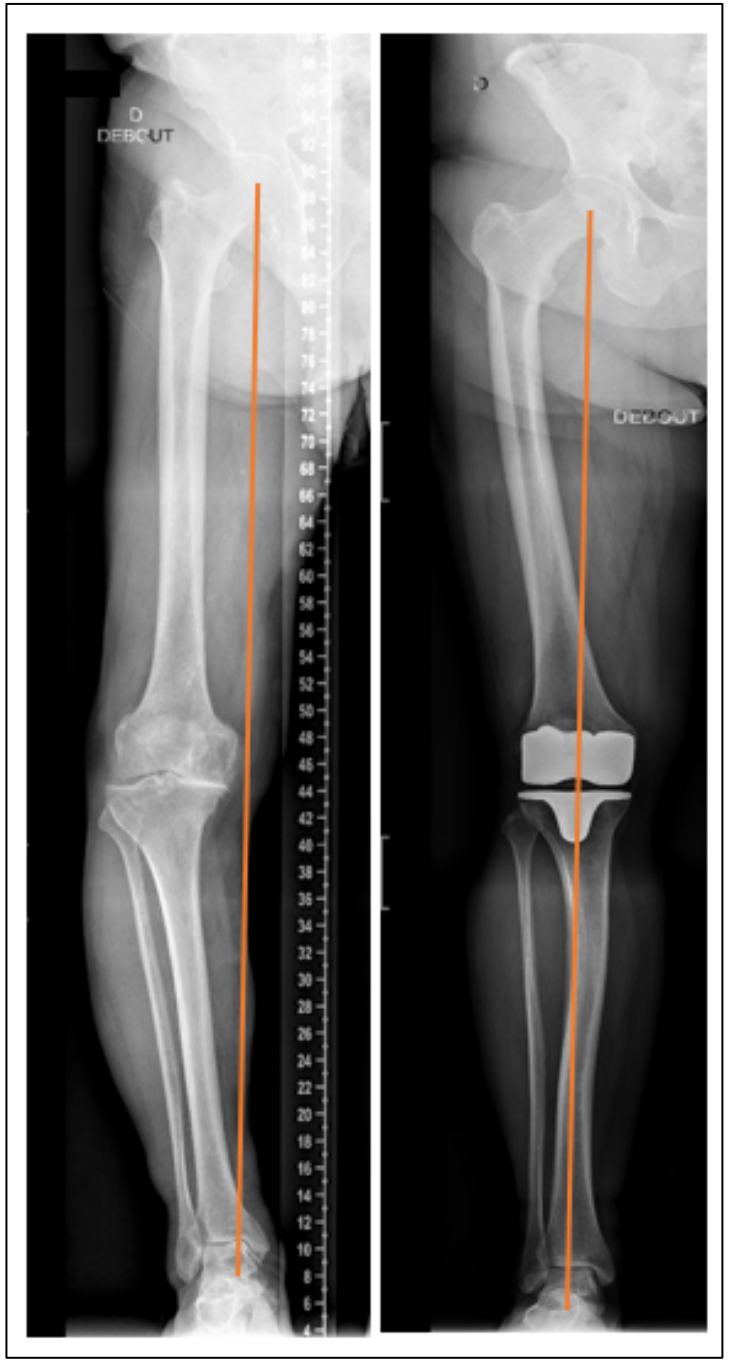
D
DEBCUT
DEBCUT

Théorie de l'Alignement Anatomique
Approche systématique

Clin Orthop Relat Res. 1985 Jan-Feb;(192):23-33.

Total joint arthroplasty of the knee.

Hungerford DS, Krackow KA.

- Restaurer une position plus anatomique de l'interligne
- Coupe parallèlle à l'interligne
- Obliquité de 3°
- LDFA: 9° VL
- MDFA: 3° de VR
- Ligne de Maquet passant par le centre du genou

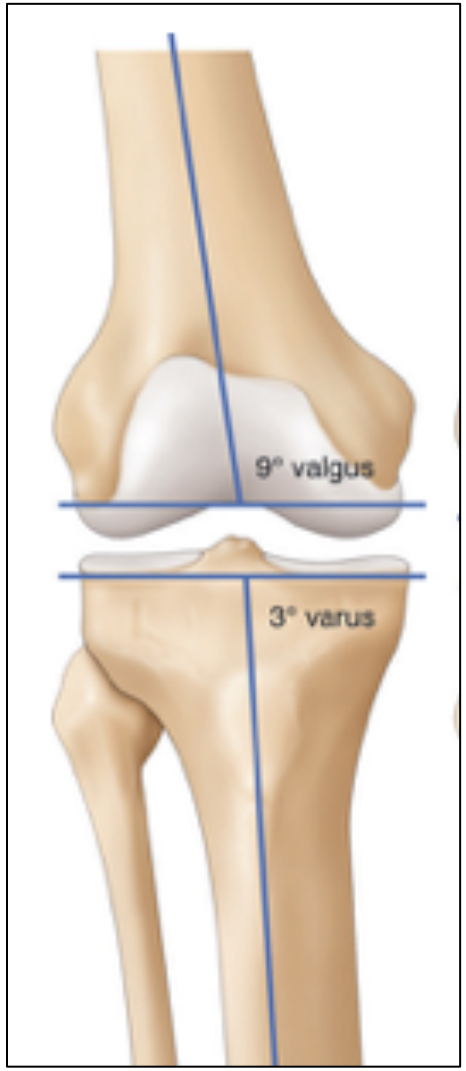

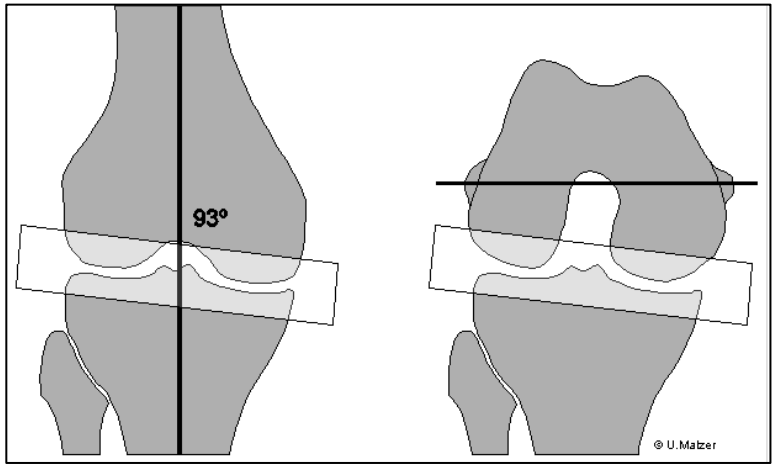

BKC
BRUSSELS KNEE CENTER

Alignement anatomique « like »
= **AM** avec 3° d'obliquité
dans l'implant

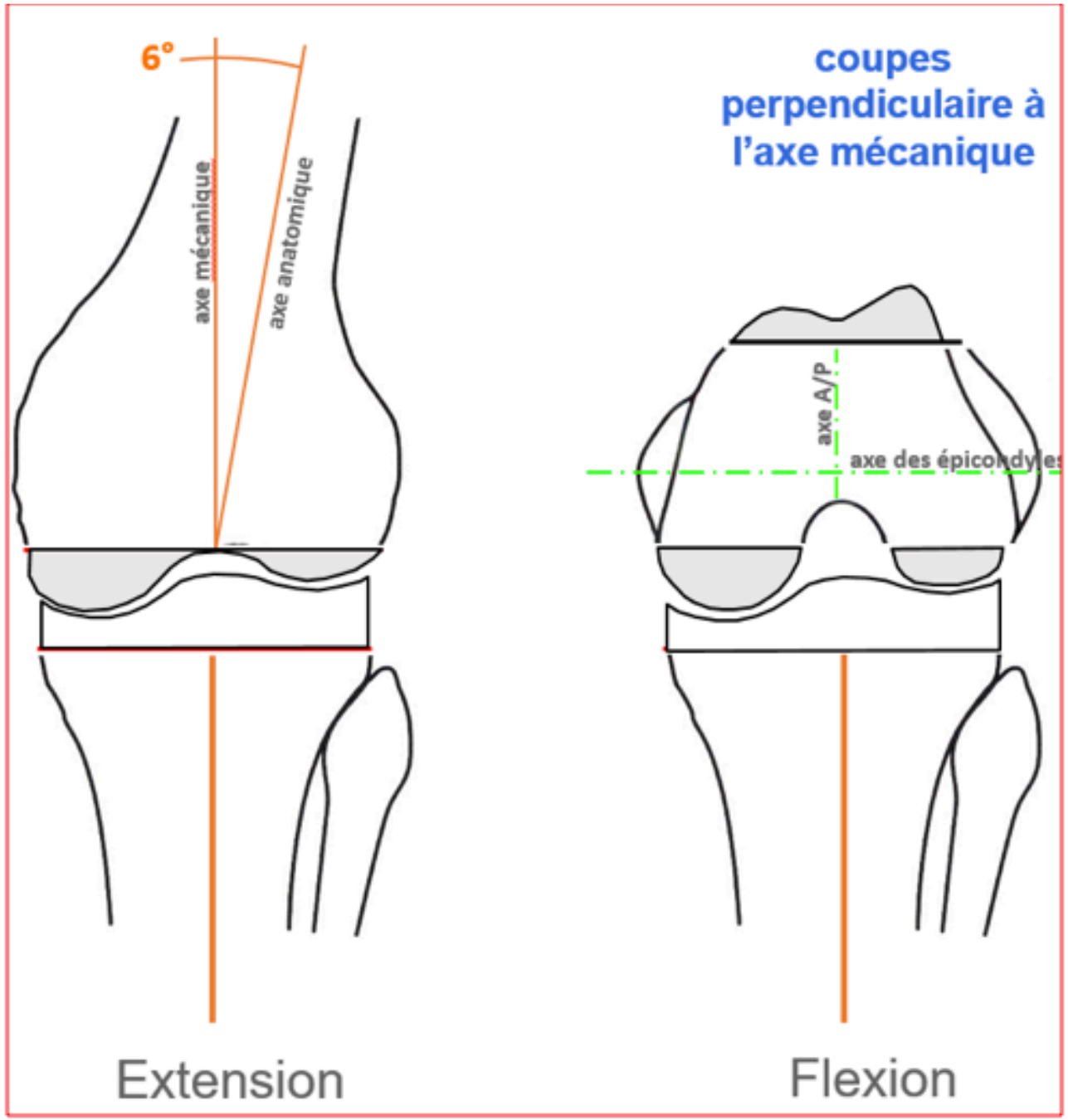

J Bone Joint Surg Am. 2010 Sep 15;92(12):2143-9. doi: 10.2106/JBJS.I.01398.

Effect of postoperative mechanical axis alignment on the fifteen-year survival of modern, cemented total knee replacements.

Parratte S[1], Pagnano MW, Trousdale RT, Berry DJ.

CONCLUSIONS: A postoperative mechanical axis of 0° ± 3° did not improve the fifteen-year implant survival rate following these 398 modern total knee arthroplasties. We believe that describing alignment as a dichotomous variable (aligned versus malaligned) on the basis of a mechanical axis goal of 0° ± 3° is of little practical value for predicting the durability of modern total knee arthroplasty implants.

Pas d'effet délétère d'un alignement postopératoire anormal

Bone Joint J. 2017 Oct;99-B(10):1319-1328. doi: 10.1302/0301-620X.99B10.BJJ-2017-0066.R1.

Do varus or valgus outliers have higher forces in the medial or lateral compartments than those which are in-range after a kinematically aligned total knee arthroplasty? limb and joint line alignment after kinematically aligned total knee arthroplasty.

Shelton TJ[1], Nedopil AJ[1], Howell SM[2], Hull ML[3].

CONCLUSION: Although kinematically aligned TKA has a high proportion of varus or valgus outliers using mechanically aligned criteria, the intra-operative forces in the medial and lateral compartments of patients with outlier alignment were comparable with those with in-range alignment, with no evidence of overload of the medial or lateral compartment of the knee. Cite this article: *Bone Joint J* 2017;99-B:1319-28.

©2017 The British Editorial Society of Bone & Joint Surgery.

BKC
BRUSSELS KNEE CENTER

Théorie de l'alignement constitutionnel en varus

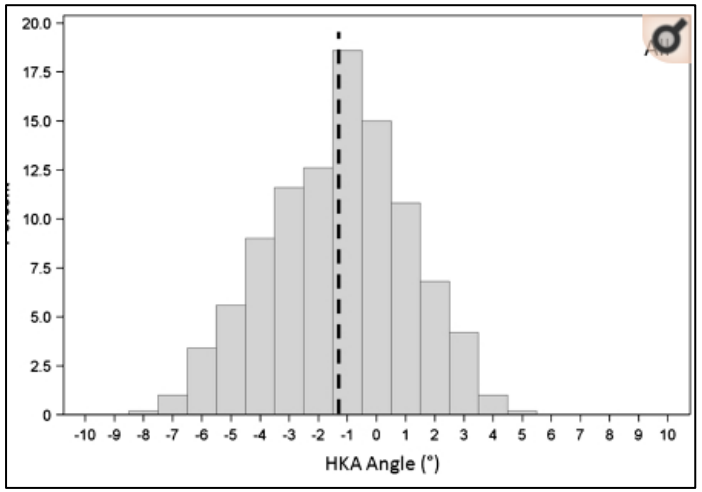

Clin Orthop Relat Res. 2012 Jan;470(1):45-53. doi: 10.1007/s11999-011-1936-5.

The Chitranjan Ranawat award: is neutral mechanical alignment normal for all patients? The concept of constitutional varus.

Bellemans J[1], Colyn W, Vandenneucker H, Victor J.

RESULTS: Thirty-two percent of men and 17% of women had constitutional varus knees with a natural mechanical alignment of 3° varus or more. Constitutional varus was associated with increased sports activity during growth, increased femoral varus bowing, an increased varus femoral neck-shaft angle, and an increased femoral anatomic mechanical angle.

CONCLUSIONS: An important fraction of the normal population has a natural alignment at the end of growth of 3° varus or more. This might be a consequence of Hueter-Volkmann's law. Restoration of mechanical alignment to neutral in these cases may not be desirable and would be unnatural for them.

- 70% de la population 2-3° de VR
- HKA=180° = Surcorrection.
- Obliquité de 3°

BKC
BRUSSELS KNEE CENTER

Théorie de l'Alignement Cinématique

Clin Orthop Relat Res. 2013 Mar;471(3):1000-7. doi: 10.1007/s11999-012-2613-z. Epub 2012 Sep 21.

Does a kinematically aligned total knee arthroplasty restore function without failure regardless of alignment category?

Howell SM[1], Howell SJ, Kuznik KT, Cohen J, Hull ML.

Clin Orthop Relat Res. 1993 May;(290):259-68.

The axes of rotation of the knee.

Hollister AM[1], Jatana S, Singh AK, Sullivan WW, Lupichuk AG.

- Restaurer l'axe cinématique naturel du genou = un **vrai resurfaçage**
- Compensation uniquement de l'usure = **Théorie de UNI**
- Technique **spécifique au patient**

BKC
BRUSSELS KNEE CENTER

Risques

- Descellement précoce par lift off de l'implant
- Usure précoce du polyethylene
- Complications tibiales

→ **Sur stress majoré du CI**

BKC
BRUSSELS KNEE CENTER

Technique Mécanique ou cinématique modifiée

Technique d'alignement mécanique ajustée

- Maintien de 3° max de VR ou VL en fonction de la déformation
- Geste sur le fémur
- Tibia aligné sur l'axe mécanique

Technique d'alignement cinématique retreinte

- Pour varus important ou obliquité de >5°
- Usure essentiellement tibiale
- Correction de la coupe tibiale avec majoration de la perte osseuse pour être en zone de sécurité au niveau alignement

BKC
BRUSSELS KNEE CENTER

Quid de la fonction entre AM et AC?

Alignment options for total knee arthroplasty: A systematic review

C. Rivière [a,*], F. Iranpour [a], E. Auvinet [a], S. Howell [b], P.-A. Vendittoli [c], J. Cobb [a], S. Parratte [d]

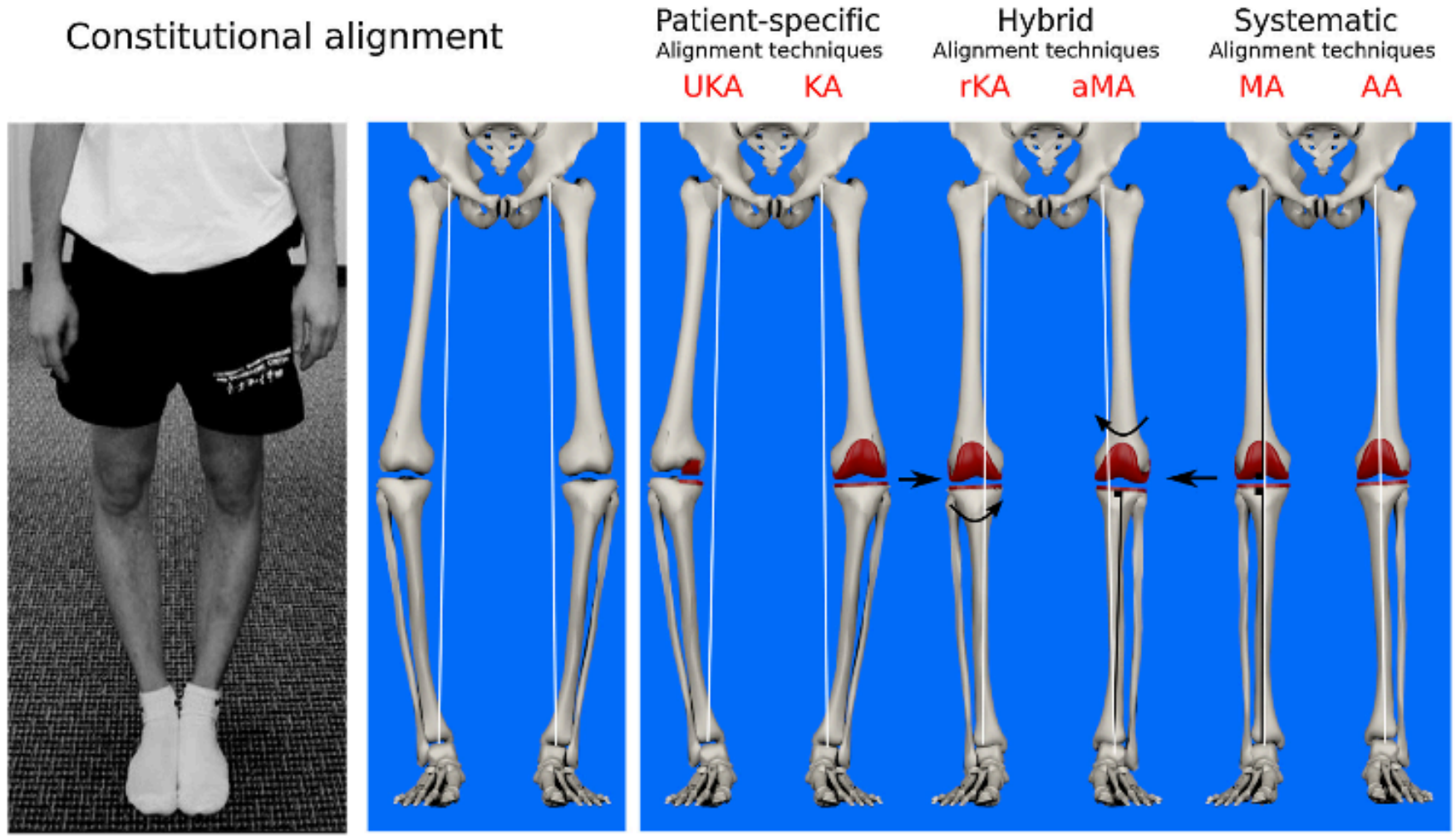

Fig. 2. Different philosophies for implanting a TKA. To illustrate this classification, a knee with severe constitutional varus deformity has been selected. MA: Mechanical Alignment technique; AA: Anatomical Alignment technique; aMA: adjusted Mechanical Alignment technique; rKA: restricted Kinematic Alignment technique, UKA: Unicompartmental Knee Arthroplasty.

BKC
BRUSSELS KNEE CENTER

Table 1
Technical differences between mechanic and kinematic alignment techniques.

	KA technique "patient specific approach"	MA technique "systematic approach"
F component sagittal rotational positioning (F distal cut)	Follow F bowing (3° flexion relative to the sagittal F mechanical axis)	Follow F bowing (3° flexion relative to the sagittal F mechanical axis)
F component frontal rotational positioning (F distal cut)	Parallel to the frontal femoral slope after correction for wear	Perpendicular to the femoral mechanical axis
F component horizontal rotational positioning (F anterior and posterior cuts)	Neutral rotation relative to PCL Measured resection technique only	External rotation relative to PCL Measured resection or gap-balancing techniques
F component anteroposterior translational positioning	Posterior referencing technique only (compromise done on the trochlear offset)	Posterior or anterior referencing techniques (compromise done on the flexion gap or on the trochlear offset)
F component mediolateral translational positioning	Centered on the notch	Centered on the notch or slightly lateralized to optimize patella tracking
T component frontal rotational positioning (Tcut)	Parallel to the frontal tibial slope after correction for wear (no attention is paid to the ankle)	Perpendicular to the tibial mechanical axis
T component sagittal rotational positioning (T cut)	Parallel to medial plateau slope	Between 2 and 7° posterior slope relative to the sagittal T mechanical axis
T component horizontal rotational positioning	Parallel to lateral plateau axis [no attention is paid to ATT)	Towards ATT
FT soft tissues balancing	No (goal is to restore constitutional knee laxity in flexion and extension)	Often (goal is to obtain rectangular symmetric flexion and extension gaps)
PF soft tissues balancing	No	Often

BKC
BRUSSELS KNEE CENTER

Perte osseuse et axe rotatoire

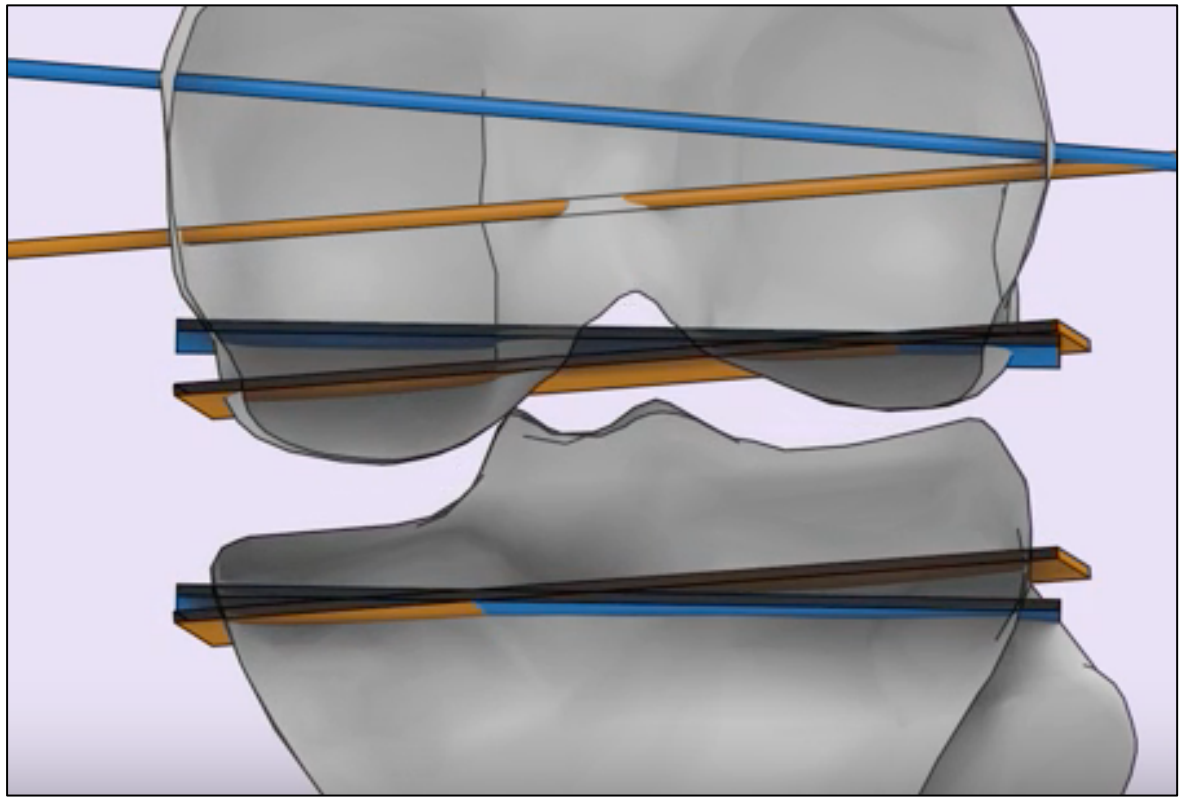



BKC
BRUSSELS KNEE CENTER

Techniques	cinématique	mécanique
avantages	• Moins de perte osseuse • Moins de release ligamentaire • Reproduction de l'obliquité articulaire • Tracking rotulien • Meilleur cinématique du genou	• Répartition identique des charges • Durée de vie • Moins d'usure
désavantages	• Usure • Descellement précoce sur déformation importante >5°	• Pas un genou naturel • Insatisfaction • Plus de perte osseuse • instabilité

BKC
BRUSSELS KNEE CENTER

Knee types	1	2	3a	3b	3c	4
Complexity of procedure	Simple	Complex				
Description	After correction of articular wear there is no severe frontal pathoanatomy	After correction of articular wear there is a severe (constitutional or post-traumatic) frontal pathoanatomy				History of non traumatic patella instability
HKA after correction of articular wear	≤ 5°varus or valgus	>5° varus	>5° valgus with "tibia valga" present	>5° valgus without "tibia valga"	Valgus knee with severe MCL distension	
Possible alternative techniques for TKA	KA	rKA with tibial adjustment or "KA + realignment osteotomy" (KA ?)		rKA with tibial and femoral adjustment or "KA + realignment osteotomy" (prevent excessive joint line obliquity)	Not indicated	"KA + MPFL reconstruction" +/- lateral retinaculum release and VMO plasty +/- extensor mechanism realignment

Fig. 5. Algorithm for use of more anatomical surgical techniques for total knee arthroplasty. Alternative techniques of implant positioning are suggested and procedure(s) (osteotomy, ligament reconstruction, and so on) are recommended depending the type of pathoanatomy. KA: Kinematic Alignment technique; rKA: Kinematic Alignment technique; MCL: Medial Collateral Ligament; MPFL: Medial Patello-Femoral Ligament; VMO: Vast Medial Oblique.

BKC BRUSSELS KNEE CENTER

ETUDES comparatives sur la fonction entre AM et AC

Bone Joint J. 2016 Oct;98-B(10):1360-1368.

The early outcome of kinematic versus mechanical alignment in total knee arthroplasty: a prospective randomised control trial.

Waterson HB[1], Clement ND[1], Eyres KS[2], Mandalia VI[2], Toms AD[2].

CONCLUSION: Kinematically aligned TKAs appear to have comparable short-term results to mechanically aligned TKAs with no significant differences in function one year post-operatively. Further research is required to see if any theoretical long-term functional benefits of kinematic alignment are realised or if there are any potential effects on implant survival. Cite this article: Bone Joint J 2016;98-B:1360-8.

BKC
BRUSSELS KNEE CENTER

Clin Orthop Relat Res. 2017 Jan;475(1):9-20. doi: 10.1007/s11999-016-4844-x.

The Chitranjan S. Ranawat Award : No Difference in 2-year Functional Outcomes Using Kinematic versus Mechanical Alignment in TKA: A Randomized Controlled Clinical Trial.

Young SW[1,2], Walker ML[3], Bayan A[3], Briant-Evans T[4], Pavlou P[5], Farrington B[3].

CONCLUSIONS: We found no difference in 2-year patient-reported outcome scores in TKAs implanted using the KA versus an MA technique. The theoretical advantages of improved pain and function that form the basis of the design rationale of KA were not observed in this study. Currently, it is unknown whether the alterations in component alignment seen with KA will compromise long-term survivorship of TKA. In this study, we were unable to demonstrate an advantage to KA in terms of pain or function that would justify this risk.

BKC
BRUSSELS KNEE CENTER

Knee Surg Sports Traumatol Arthrosc. 2019 May;27(5):1529-1534. doi: 10.1007/s00167-018-5284-9. Epub 2018 Nov 12.

Kinematic alignment in total knee arthroplasty leads to a better restoration of patellar kinematics compared to mechanic alignment.

Keshmiri A[1], Maderbacher G[2], Baier C[2], Benditz A[2], Grifka J[2], Greimel F[2].

RESULTS: There was a statistically significant difference between natural patellar kinematics and both implantation techniques analysing mediolateral shift. Patellar lateral tilt showed significant better results in the kinematically compared to the mechanically aligned TKAs. In terms of patella rotation, the patella of both mechanically and kinematically aligned TKAs showed significant higher values for external rotation compared to the natural knee. Regarding epicondylar distance again a significant better restoration of natural kinematics could be found in the kinematically aligned TKAs.

BKC
BRUSSELS KNEE CENTER

Knee Surg Sports Traumatol Arthrosc. 2018 Jun;26(6):1629-1635. doi: 10.1007/s00167-017-4788-z. Epub 2017 Dec 4.

Kinematically aligned total knee arthroplasty reduces knee adduction moment more than mechanically aligned total knee arthroplasty.

Niki Y[1], Nagura T[2], Nagai K[1], Kobayashi S[1], Harato K[1].

CONCLUSIONS: In KA-TKA, joint line obliquity reduced peak KAM during gait, despite slight varus limb alignment, and this reduced KAM in KA-TKA can tolerate constitutional varus alignment. In clinical settings, KA-TKA thus represents a promising technical option for patients with large coronal bowing of the shaft carrying a risk of increased KAM after TKA.

BKC
BRUSSELS KNEE CENTER

Knee Surg Sports Traumatol Arthrosc. 2019 May;27(5):1410-1417. doi: 10.1007/s00167-018-5174-1. Epub 2018 Oct 1.

Kinematic alignment in total knee arthroplasty better reproduces normal gait than mechanical alignment.

Blakeney W[1], Clément J[2], Desmeules F[2,3], Hagemeister N[4,5], Rivière C[6], Vendittoli PA[7,8].

CONCLUSIONS: The knee kinematics of patients with kinematically aligned TKAs more closely resembled that of normal healthy controls than that of patients with mechanically aligned TKAs. This may be the result of a better restoration of the individual's knee anatomy and ligament tension. A return to normal gait parameters post-TKA will lead to improved clinical outcomes and greater patient satisfaction.

BKC
BRUSSELS KNEE CENTER

Knee Surg Sports Traumatol Arthrosc. 2019 May;27(5):1427-1433. doi: 10.1007/s00167-018-5105-1. Epub 2018 Aug 21.

Kinematic component alignment in total knee arthroplasty leads to better restoration of natural tibiofemoral kinematics compared to mechanic alignment.

CONCLUSION: In the present study setting kinematically aligned total knee arthroplasties showed more natural and physiological tibiofemoral kinematic pattern with regard to tibial internal rotation or femoral rollback, respectively, and tibial adduction than mechanically aligned total knee arthroplasties. While these results may support promising early clinical results of kinematical alignment proposing a better function, long-term results especially implant survival need to be awaited.

BKC
BRUSSELS KNEE CENTER

Conclusion: Cinématique > Mécanique

- Moins de Geste tissulaire, moins de perte osseuse
- Moins d'Instabilité
- Amélioration dans la marche et de la cinématique globale du genou
- Amélioration du tracking rotulien
- Amélioration de l'index de satisfaction du patient
- Quid sur le long terme?

BKC
BRUSSELS KNEE CENTER

Acta Orthop Belg. 2015 Sep;81(3):471-7.

Current opinions about coronal plane alignment in total knee arthroplasty: A survey article.

Thienpont E, Cornu O, Bellemans J, Victor J.

CONCLUSIONS: Neutral mechanical axis with a joint line parallel to the floor and a centrally running load bearing axis remains the central scope of the surveyed surgeons. Because of the literature on residual varus it becomes more acceptable for the orthopaedic community to accept this type of outlier before aiming at a surgical correction.

BKC
BRUSSELS KNEE CENTER

Changer d’opinion

L’apport de la robotique peut nous y aider

BKC
BRUSSELS KNEE CENTER

Merci